Possible addition to the slit lamp section of the teaching notes for MBCHB313
A/P Jennifer P Craig

In the image below, the beam of the slit lamp is directed towards the patient's eye. A lesion at the head of the arrows below, would be positioned at what anatomical location in the eye?

Choose from the following:
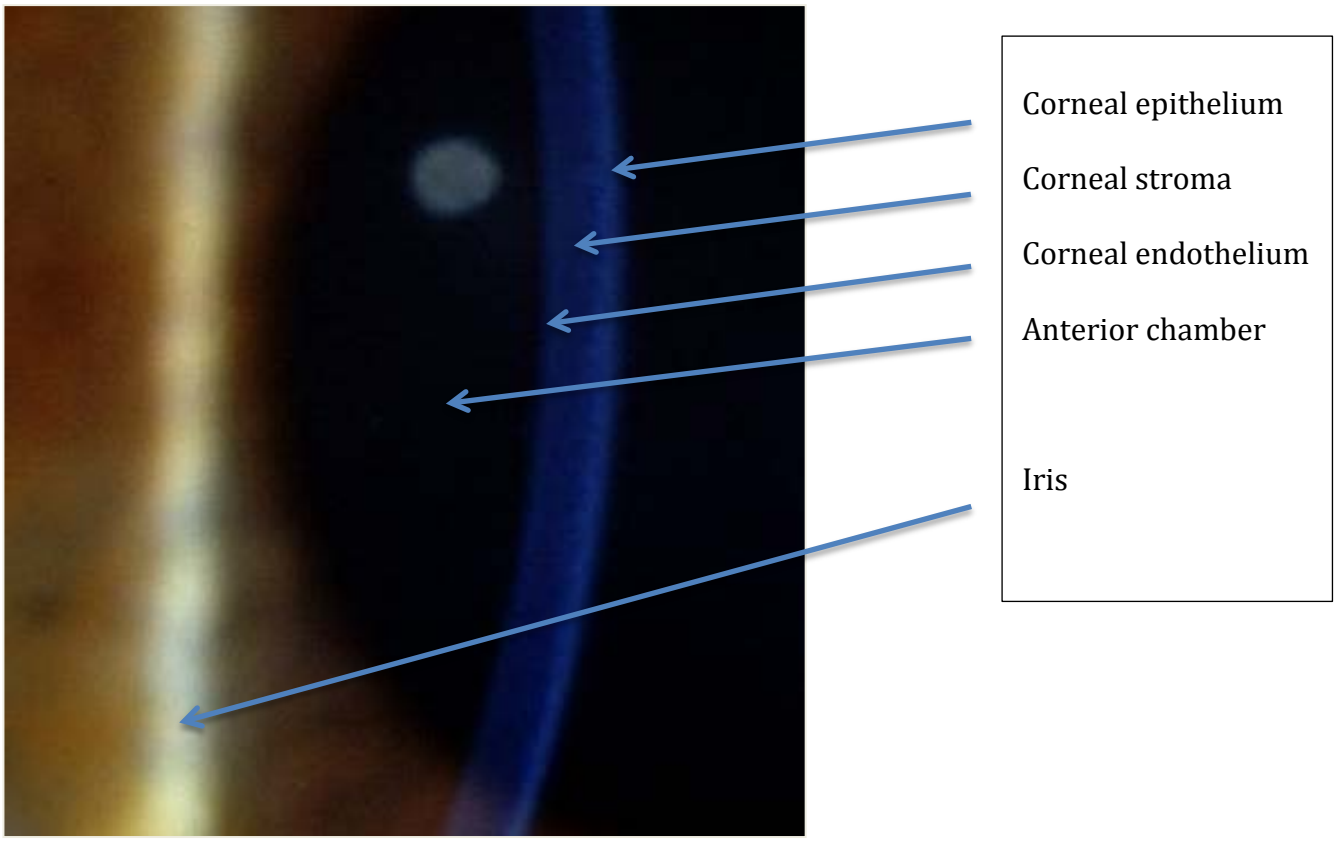
- corneal stroma
- iris
- corneal endothelium
- anterior chamber
- corneal stroma